

# UNDERSTANDING APPENDIX CANCER & PSEUDOMYXOMA PERITONEI

## Overview, Symptoms, Diagnosis, and Treatment

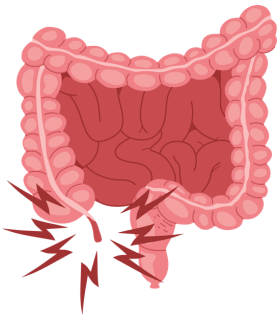
### Overview

Appendix cancer starts with a tumor in the cells of the appendix.

#### There are many different types of tumors:

1. Low-grade mucinous neoplasm of the appendix (LAMN),
2. High-grade mucinous neoplasm of the appendix (HAMN),
3. Goblet cell carcinoid (defined by a unique combination of two types of cancer cells – neuroendocrine [carcinoid] and epithelial [adenocarcinoma]), adenocarcinoma, further classified as:
  - a. well-differentiated,
  - b. moderately-differentiated,
  - c. poorly-differentiated and
  - d. signet ring cell (SRC).

Appendiceal tumors frequently spread inside the abdominal cavity. Depending on the type of tumor, this can lead to a condition called peritoneal carcinomatosis or peritoneal surface malignancy.



**Pseudomyxoma peritonei (PMP)** is the progressive accumulation of mucus-secreting or mucinous tumor cells within the abdomen and pelvis after an appendiceal tumor bursts through the wall and spreads mucinous cells throughout the surrounding surfaces. As mucinous tumor cells accumulate, the abdominal area becomes swollen and digestive function becomes impaired.

In very rare cases, pseudomyxoma peritonei can arise from tumors located in organs other than the appendix, but the vast majority arise from appendiceal tumors.

### Incidence, Symptoms & Diagnosis

#### Incidence

Cancers and tumors of the appendix are extremely rare with an estimated incidence of 2-9 per 1,000,000 people. The average age of onset is between 50 and 55 years, and they affect men and women equally.

#### Symptoms

Appendix cancer and PMP are often misdiagnosed because in many cases, relatively common symptoms such as abdominal pain, increased abdominal girth, bloating, hernia, ascites, and ovarian cysts or tumors or infertility in women are misunderstood for years. Many women are initially misdiagnosed with ovarian cancer.

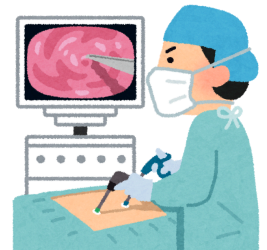### Diagnosis

For many patients, appendix cancer and/or PMP are discovered during an unrelated surgical procedure. The following diagnostic tests are also commonly used in diagnosing appendix cancer and PMP:

- CT scan of the chest, abdomen and pelvis.
- MRI of the abdomen and pelvis (special protocols and expertise at reading MRIs are required to get the maximal benefit of this technology).
- Diagnostic laparoscopy.
- Blood tests (tumor markers). Some tumor markers in the blood have been shown to be indicative of appendix cancer and/or PMP activity in some (but not all) patients, particularly CEA, CA-125, & CA 19-9.

### Treatment

Treatment varies depending on the stage of disease and the subtype, and whether the cancer is localized to the appendix or has spread. For LAMN that have not spread in the abdomen, an appendectomy is all that is required. For moderately- differentiated, poorly-differentiated and signet ring cell appendiceal cancers, surgical removal of the right side of the colon (right hemicolectomy) is recommended to ensure that all the disease has been removed and to test the regional lymph nodes for any cancer cells.



For tumors and cancers that have spread into the abdominal cavity or into the local lymph nodes, intravenous chemotherapy using existing colon cancer regimens and/or additional surgery to remove the cancer is recommended, in particular cytoreductive surgery (CRS) accompanied by heated intraperitoneal chemotherapy (HIPEC), delivered directly into the abdomen.

### Cytoreductive Surgery (CRS) & Heated Intraperitoneal Chemotherapy (HIPEC)

CRS/HIPEC is the standard of care for peritoneal surface malignancies of appendiceal origin. This procedure should be performed at an experienced HIPEC center. CRS/HIPEC has been shown to provide long-term survival in up to 90% of patients with low-grade pathology who are properly diagnosed and undergo this treatment early enough in the disease process to offer maximum benefit.

When patients are misdiagnosed, they are less likely to benefit from CRS/HIPEC, and even with proper diagnosis many patients are never even offered it. This treatment, unavailable to our patient population a generation ago, has turned what used to be an almost certain death sentence into hope for thousands of patients around the world.